

Name:
ID:
Geb.: **09.12.1950**
Alter: **73**

Unters.-Dat **25.04.2024**
Geschlecht: Weiblich
Auge: Rechts

Bemerkung: OD: Kleiner zentraler Gesichtsfeldausfall; fixierte Optotype wird nicht gesehen; Pseudophak; Vcc 0,80 Tonometrie 13:54 h: 13,5 mm/hg; HHD 5 18 µm

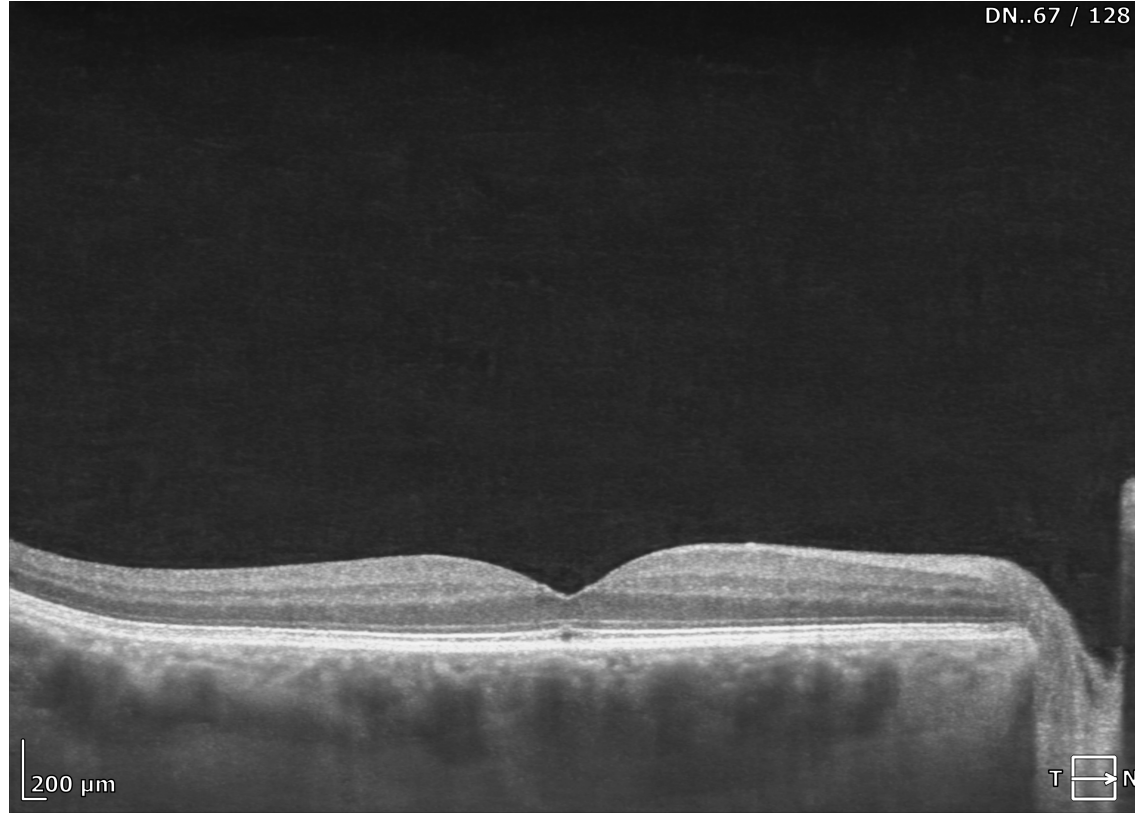
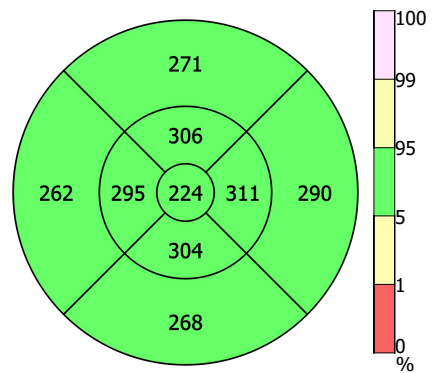
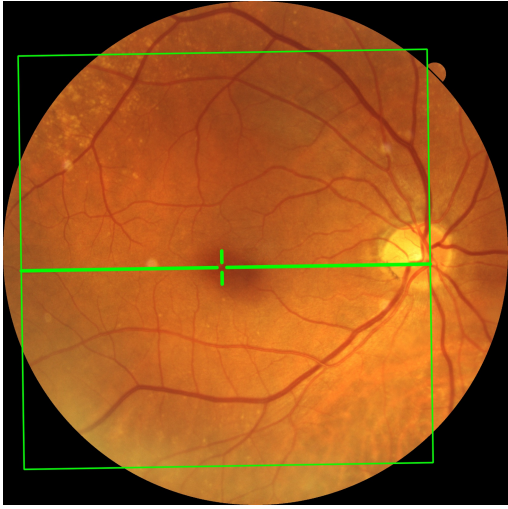
KNEPPECK
augenoptik + optometrie
Burgstr. 6, 26122 Oldenburg
optometrie@kneppeck.de
0441 15481



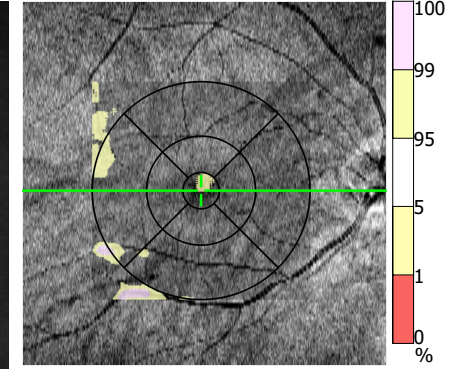
R 25.04.2024 14:02:48 QI: 10
3D 10x10 mm

MAKULA | EINZELN

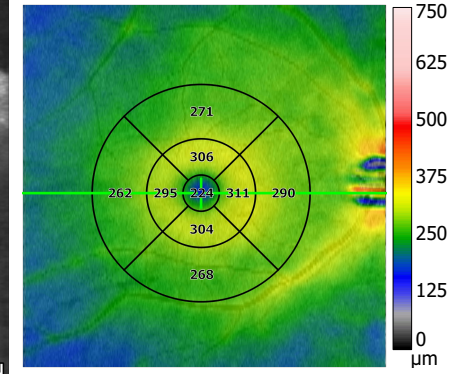
Fundusbild



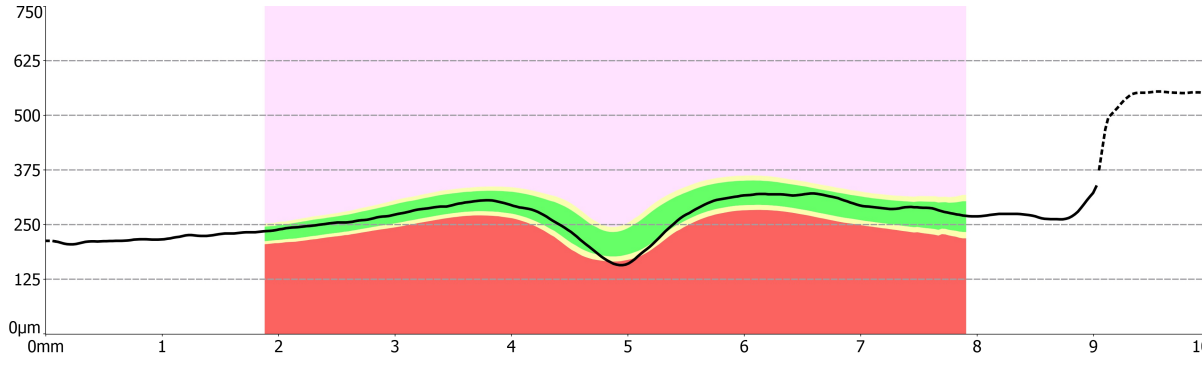
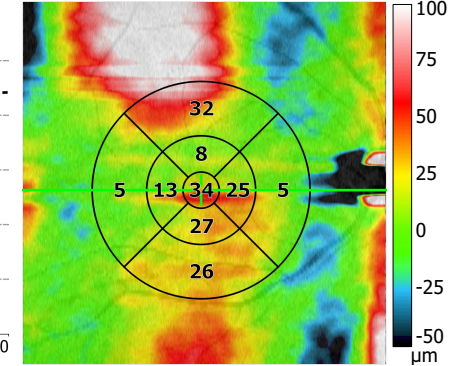
Retina Signifikanz



Netzhautdicke



RPE Verformung



ILM - OS/RPE Messungen	
Minimum in Fovea [µm]	170
Zentraler Bereich [µm]	224
Dicke der ges. Fläche [µm]	278
Volumen [mm³]	7,87